



Clinical outcomes of proximal humerus fracture using intramedullary humerus nailing system

Manjunath J, Kiran G U, Sachin M

Department of Orthopaedics, SS Institute of Medical Sciences, Davangere, Karnataka, India

Abstract

Background: The use of intramedullary nail fixation to treat surgically treated proximal humeral fractures has grown in acceptance and interest. Diaphyseal fractures of the humerus are frequent, making up between three and five percent of all fractures. Therefore, the purpose of the current study was to determine if interlocking nails are effective in treating adult patients with diaphyseal fractures of the humerus.

Materials and Methods: The study comprised 40 patients in all who met the eligibility requirements. For the first three months after the fracture union, all patients were monitored monthly. After that, they were followed up every two months until the study's conclusion. They underwent a thorough clinical examination, with particular attention paid to the range of motion in the shoulders and elbows as well as any subjective symptoms.

Results: The study's conclusion included an analysis of the general findings. 18 patients had Excellent results, 9 patients had good results, and 3 patients had poor results. 8 patients had associated fractures along with the humerus fracture.

Discussion and Conclusion: Closed intramedullary interlocking nailing is the least invasive surgical procedure available, with a lower risk of post-operative infection and a shorter length of hospital stay than other modalities. When humeral diaphyseal fractures were repaired using intramedullary interlocking nails, patients with related injuries showed excellent results, as evidenced by the shortened recovery period and early rehabilitation. Minimal surgical exposure, improved biological fixation, less disruption of soft tissues, and early mobilization of nearby joints are the benefits of intramedullary nailing.

Keywords: Intramedullary nailing, proximal humerus fracture, treatment, complications

Introduction

Fracture shaft of humerus include group of fracture where main fracture line lies distal to surgical neck of humerus and proximal to supracondylar ridge distally. It accounts for nearly 3.5% of all different type of fractures of bone. 5% of injuries were associated with open wound and 63% were of simple fracture pattern.

Treatment for simple humeral fractures involves reduction and immobilization of the arm; approximately 90% of cases result in good union. A hanging cast, functional bracing, Velpaadressing, and shoulder surgery are some of the conservative therapy options that are available. "Chanley" The first orthopedic surgeon prefers a conservative approach.

However, with recent advancement in fracture fixation technique and biomaterial, success of improved surgical treatment and low rates complication rate and better efficacy of managing complication.

In recent times Poly trauma due to road traffic accidents, markedly obese patients, elderly with osteoporosis, Segmental fracture, Fracture with more than 50% of comminution all require operative intervention. Lastly Failure of conservative treatment and non-Compliance of patient to bulky U cast and increased chance of shoulder and elbow restriction has prompted for operative internal fixations.

There are two distinct models available for individuals with surgical indications: intramedullary nailing (with open and closed techniques) and compression plates. Each model has pros and cons. Although we can accomplish more rigorous fixation with plate and screw fixation, there is significantly less soft tissue manipulation at the fracture site when intramedullary nailing is used [6, 7].

The use of intramedullary nail fixation to treat surgically treated proximal humeral fractures has grown in acceptance and interest. These implants have traditionally been utilized to correct pathologic humeral diaphyseal fractures; however, advances in surgical methods and implant design have made it possible to reliably catch segments of tuberosity fractures while preserving the advantages of percutaneous device implantation [8].

Furthermore, disruption of the vascular supply to the humeral head and fracture segments can be avoided as a result of the device being inserted close to the fracture site. This could increase tuberosity healing and lower the incidence of avascular necrosis. Ultimately, more 3- and 4-part fractures can be reliably treated with intramedullary fixation thanks to improvements in implant design and improved knowledge of surgical technique [8, 9].

Materials and Methods

The present study was done in the department of Orthopaedics, SS institute of medical sciences davangere, karnataka, India, from May 2023 to April 2024. The present is the prospective study conducted on the patients diagnosed with traumatic diaphyseal humerus fracture. The ethical committee of the institute was informed about the objective of the study and the ethical clearance certificate was obtained from them.

The following were the inclusion criteria: Acute humeral diaphyseal fracture, age greater than sixteen, segmental fracture, and complex Gustilo's Type I fracture.

The following were the exclusion criteria: Under 16 years old, Gustilo's type II and III compound fracture, medical ineligibility for surgery, fracture with neurovascular impairments.

30 patients satisfied the criteria and were enrolled in the study.

In order to determine the mechanism of damage and the extent of trauma, a thorough history was obtained from the patients and/or attendants. The patients' overall health and the extent of the local harm were then examined clinically. The vital signs were noted in general condition. Every precaution was taken to identify shock and any related injuries. After a local inspection, it was discovered that the damaged arm was to be flexed at the elbow, adducted at the shoulder, and supported at the elbow by the other hand. We searched for and recorded swelling, deformity, loss of function, and nerve damage.

Upon palpation, the affected arm appeared sensitive and had abnormal movement as well as crepitus and shortening. Pallor, capillary refilling, radial artery pulsations, and paraesthesia at the fingertips were used to measure distal vascularity. Dorsiflexion of the metacarpo-phalangeal joint and active wrist were used to assess the radial nerve. Sensation within the first web space's autonomous zone was examined for abnormalities.

Anteroposterior and lateral images, or standard radiography, of the humerus were acquired. In every view, the elbow and shoulder joints were visible. The limb was sling-immobilized in a U-Slab. They administered injectable analgesics. Each patient received a thorough explanation of the operating procedure and its benefits, and their informed consent was obtained. After undergoing a standard investigation, the patients scheduled for surgery were referred to the doctor for assessment of surgical suitability.

Antegrade locking nail was used in the study for fracture in any part of humerus. Nailing was done through minimal invasive approach of shoulder with nail entry site medial to greater tuberosity and just lateral to articular margin. After placing Nail of appropriate size, nail was locked proximally and distally under C arm guidance. Post operatively all patients were initiated on active shoulder and elbow mobilization exercise periodic radiographic evaluation was carried out to look for union to assess the need for additional procedure, Position of the Implant, Evidence of any metal reaction/infection and to check for complication. Functional evaluation was done on the basis of Local tenderness, Persistent wrist drop, Elbow function, Shoulder function (constant and Murley score). Reoperation was done in some case for bone grafting. All patients were evaluated on basis of possible outcome when any two criteria fell into separate category, lower category was selected to classify the outcome.

Post op care: The operated arm was covered with a crepe bandage, and an arm pouch was provided. Following surgery, the patients were instructed to move their wrist joints and fingers. On the third postoperative day, the wound was examined. On the sixth post-operative day, or after five days of IV antibiotics, the patients were released from the hospital; they were instructed to move their fingers, wrists, and shoulders while wearing an arm pouch. It was forbidden for them to lift heavy objects or exert more strain on the injured limb. On the twelfth postoperative day, during the follow-up, the sutures and staples were removed, and antero-posterior and lateral views of the x-ray were taken.

Follow Up

For the first three months after the fracture union, all patients were monitored monthly. After that, they were

followed up every two months until the study's conclusion. They underwent a thorough clinical examination, with particular attention paid to the range of motion in the shoulders and elbows as well as any subjective symptoms. AP and lateral views of the X-rays were acquired, and evidence of union were observed. When there was no discernible fracture line and no sign of callus bridging the fracture site, the fracture was deemed to be radiologically united. Modified Rommens *et al.* criteria were utilized to evaluate the functional outcomes.

Case

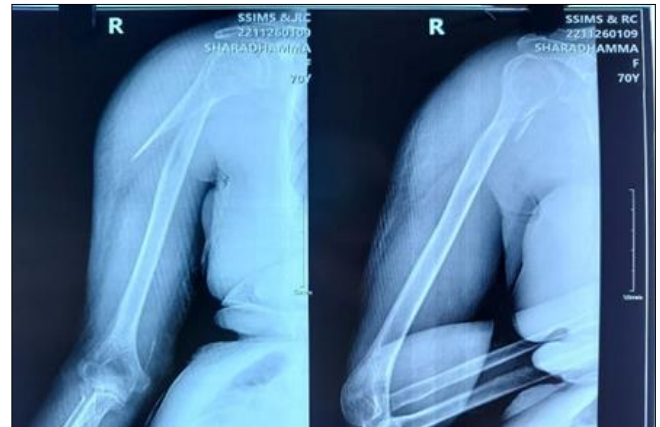

Fig 1: Pre op x ray

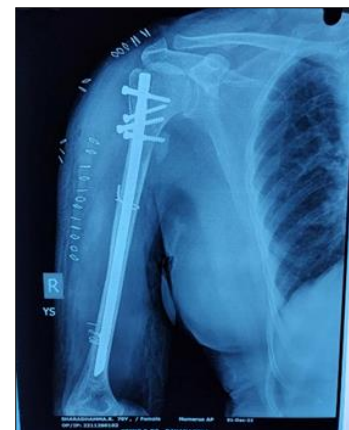

Fig 2: Immediate post op x ray

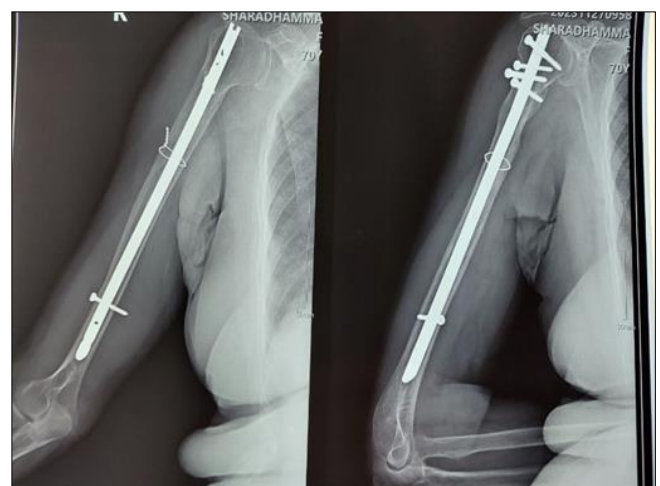


Fig 3: 6 months follow up x ray

Results

The purpose of the current study was to evaluate the effectiveness of interlocking nails in the management of adult diaphyseal fractures of the humerus. In all, thirty patients were involved in this investigation. Every patient who was included met the requirements for inclusion. Every patient was available for the duration of the follow-up. Before the procedure, the detailed medical history was documented. Patients under the age of sixteen were not allowed to participate in the study.

Patients' ages range from 16 to 60 years old, with the majority falling into the third decade of life. The patients were 37.4 years old on average. The study comprised both males and females. Males made up the majority of the patients. 10 females and 20 males were present. The right side was more affected than the left side. 12 patients had fractures on their left side, and 18 patients had fractures on their right.

The study's conclusion included an analysis of the general findings. Of the patients, 18 had excellent outcomes, 9 had good results, and 3 had poor outcomes. The majority of fractures that is 20, were oblique and transverse. This series had 6 spiral fractures and 4 comminuted fractures.

Discussion

While non-operative treatment is possible for the majority of fractures, surgical intervention may be beneficial for displaced fractures or those that are at risk of non-union. Plate fixation is still the most often used implant for the surgical management of proximal humeral fractures, but worries about hardware complications like intraarticular screw penetration and high reoperation rates have sparked interest in other fixation techniques, such as all suture fixation, external fixation, and percutaneous pin pinning^[10, 11].

Anterograde intramedullary interlocking nails were used to fix 30 acute humeral diaphyseal fractures in this study in order to assess the clinical result and associated nailing complications. We have assessed our results and contrasted them with those of other research that chose different treatment techniques, including intramedullary interlocking nailing, for humeral fractures.

Out of the 30 patients in our series, 27 had excellent or good results in the current study. Overall, intramedullary interlocking nailing results reported by different authors are comparable to the current dataset. The percentage of patients who achieve excellent or good results varies from 75% to 100% when different authors use different treatment approaches. The overall excellent or good result for our study was 90%.

Our outcome in this series was similar to what the other authors had accomplished.

The impingement of the nail over the rotator cuff resulted in shoulder stiffness and movement pain, which were the causes of the poor outcome. This could be prevented by carefully choosing the nail size, pushing the nail deeply into the bone, repairing the rotator cuff prior to closure, and aggressively starting shoulder and elbow exercises after surgery. Better outcomes can only be achieved with patient education and a carefully thought-out rehabilitation program. Intramedullary interlocking nail repair of humerus diaphyseal fractures leads to fewer complications and higher patient satisfaction if these guidelines are followed.

Conclusion

Closed intramedullary interlocking nailing is the least invasive surgical procedure available, with a lower risk of post-operative infection and a shorter length of hospital stay than other modalities. When humeral diaphyseal fractures were repaired using intramedullary interlocking nails, patients with related injuries showed excellent results, as evidenced by the shortened recovery period and early rehabilitation. Minimal surgical exposure, improved biological fixation, less disruption of soft tissues, and early mobilization of nearby joints are the benefits of intramedullary nailing.

References

1. Fernandez DL, Jupiter JB. Fractures of the distal radius: A practical approach to management. Springer Science & Business Media, 2002.
2. Salzer M, Knahr K, Locke H, Stärk N, Matejovsky Z, Plenk H, *et al.* A bioceramic endoprosthesis for the replacement of the proximal humerus. Archives of Orthopaedic and Traumatic Surgery, 1979;93:169-84.
3. Patel B, DeGroot H. Evaluation of the risk of pathologic fractures secondary to metastatic bone disease. Orthopedics, 2001;24:612-7.
4. Fausto Sterling A. Your use of the JSTOR archive indicates your acceptance of the Terms & Conditions of Use, available at. Signs, 2005;30:1491-527.
5. Hedin H. Surgical treatment of femoral fractures in children: Comparison between external fixation and elastic intramedullary nails.
6. Kivi MM, Soleymanha M. Haghparast-Ghadim Limudahi Z. Treatment outcome of intramedullary fixation with a locked rigid nail in humeral shaft fractures. Archives of Bone and Joint Surgery, 2016;4:47.
7. Lekic N, Montero NM, Takemoto RC, Davidovitch RI, Egol KA. Treatment of two-part proximal humerus fractures: intramedullary nail compared to locked plating. HSS Journal®, 2012;8:86-91.
8. Sears BW, Johnston PS, Garrigues GE, Boileau P, Hatzidakis AM. Intramedullary nailing of the proximal humerus-not just for 2-part fractures.
9. Cai P, Yang Y, Xu Z, Wang Z, Zhou X, Yang T. Anatomic locking plates for complex proximal humeral fractures: anatomic neck fractures versus surgical neck fractures. Journal of Shoulder and Elbow Surgery, 2019;28:476-82.
10. Greiwe R. Proximal humerus fractures: Percutaneous fixation, proximal humeral nailing, and open reduction and internal fixation. Shoulder and Elbow Trauma and its Complications. Elsevier, 2015, 83-112.
11. Bogunovic L, Cherney SM, Rothermich MA, Gardner MJ. Biomechanical considerations for surgical stabilization of osteoporotic fractures. Orthopedic Clinics, 2013;44:183-200.
12. Tingstad EM, Wolinsky PR, Shyr Y, Johnson KD. Effect of immediate weightbearing on plated fractures of the humeral shaft. Journal of Trauma and Acute Care Surgery, 2000;49:278-80.