

Bilateral congenital absence of flexor pollicis longus tendon– A case report from south western Nigeria

Nafiu Olatunde Aigoro

MBBS, Fwacs Consultant Orthopaedic Surgeon State Hospital, Abeokuta, Ogun State And Health Haven Hospital, Abeokuta, Ogun, Nigeria

Abstract

The Flexor Pollicis Longus is an important muscle for the unique function of the thumb. Congenital absence of the Flexor Pollicis Longus tendon is rare, and is one of the variants of type 1 thumb aplasia and hypoplasia – a large spectrum of deficiencies. Absence of Flexor Pollicis Longus (FPL) without associated anomalies of thumb hypoplasia is rare, and its bilaterality is quite rare.

A case of bilateral congenital absence of Flexor Pollicis Longus without thumb hypoplasia in a 12 years old Nigerian school girl is hereby presented. Inability to flex the thumb and lack of flexion crease are prominent diagnostic features.

Keywords: absent flexor pollicis longus, thumb hypoplasia, congenital anomaly of the thumb

Introduction

The thumb is an important digit of the human hand, and functionally represents 50% of the function of the hand. It is opposable, and prehensile. Functions of the hand include pinch, grasp, grip, manual dexterity and fine motor skills [1, 2]. Congenital anomaly of the thumb is thus a serious functional and aesthetic problem than those of other digits. Thumb aplasia and hypoplasia are a spectrum of deficiencies with the congenital absence of flexor pollicis longus with or without thenar muscles hypoplasia being the rarest.

Congenital absence of Flexor Pollicis Longus without thumb hypoplasia is rare, [3, 4, 5] and only a few bilateral cases have been reported in the literature [4, 6, 7]. When it presents in adult, patient could have well adapted and no treatment may be necessary [7].

We report the case of a 12 years old Nigerian female student with bilateral congenital absence of Flexor Pollicis Longus without thumb hypoplasia. To our knowledge this is the first reported case in a Nigerian in the literature.

Case Report

T.A. is a female student who presented in our outpatient clinic with inability to flex both thumbs. Her mother has noticed the way she holds the pen while writing and any other objects. She was however able to do other activities of daily living. There was no history of trauma/injury to the thumbs. No family history of congenital musculo- skeletal abnormalities.

Physical examination showed absence of flexor creases and no dorsal wrinkles on the thumbs. There was no active flexion at the interphalangeal joint of thumbs bilaterally [figs 1, 2,] and passive flexion was 20 degrees. There were no other obvious deformities in the hands or any other part of the body. Plain radiograph showed no skeletal anomalies in the thumb of both hands.[3a, 3b] Ultrasound Scan of both hands were done depicting the absence of the FPL tendons. [Fig 4a, 4b]

MRI of the hands was not done as it was not available in the immediate environment of the facility.



Fig 1: Palm of both Hands showing lack of flexor creases on the thumbs

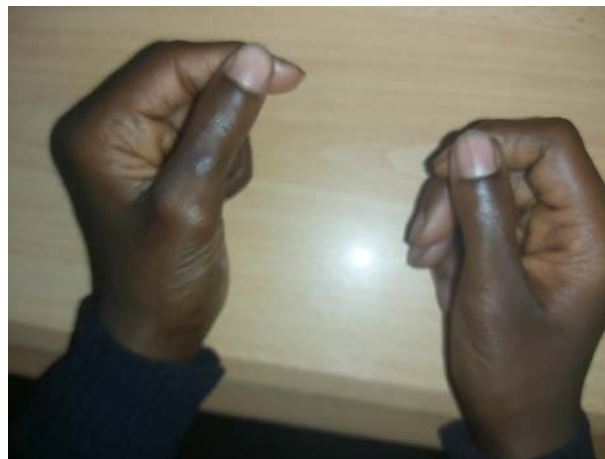

Fig 2: Dorsum of both Hands showing absence of Dorsal wrinkles on the thumbs

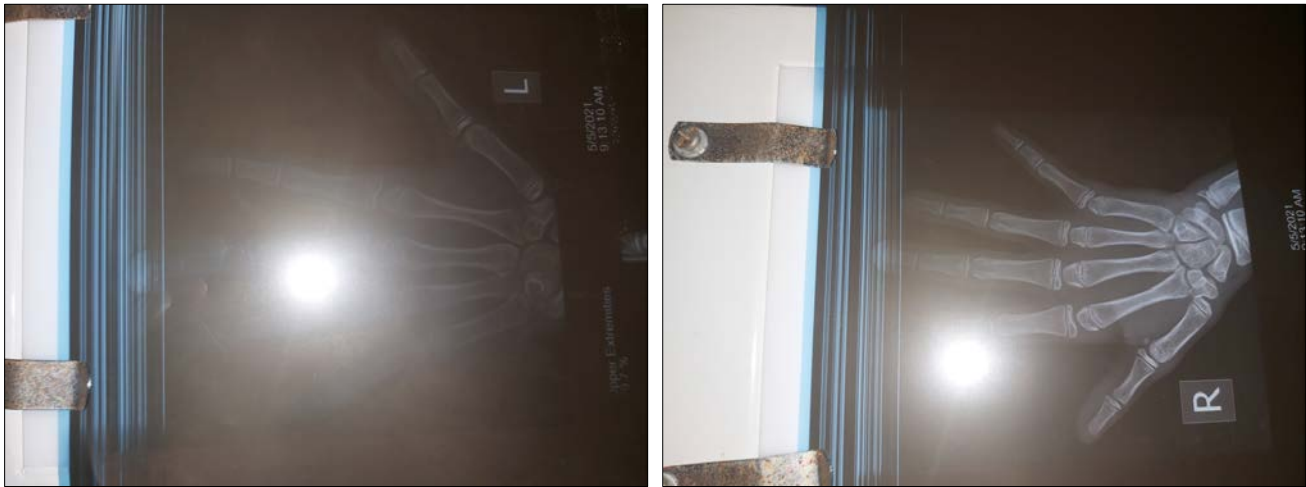

Fig 3a, 3b: Plain Radiographs of the hands showing normal skeletal pattern/ bony structure

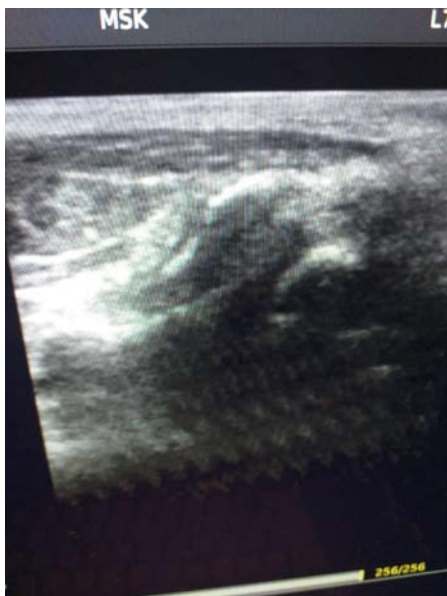


Fig 4a: Ultrasound scan of the right hand

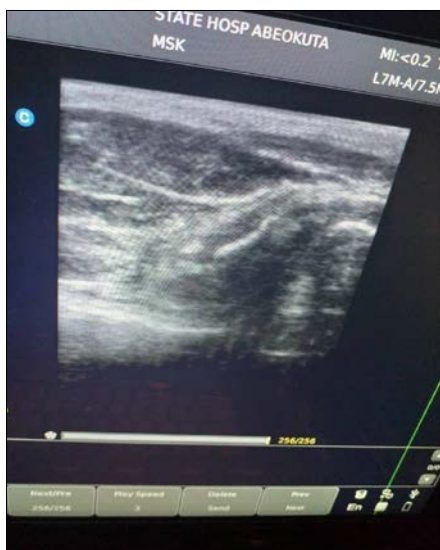

Fig 4b: Ultrasound scan of the left hand

Discussion

The thumb is the most important digit of hand and with anomalies affecting it may be quite functionally disabling. The causes of congenital inability to flex the Interphalangeal joint of thumb include absence of Flexor Pollicis Longus (FPL), congenital tenovaginitis of the FPL, partial anterior interosseous nerve palsy, traumatic rupture of the FPL and inter connection between FPL and Extensor Pollicis Longus (EPL). However, congenital absence of FPL is extremely rare [4,5]. Absence of FPL may occur with or without associate abnormalities of the thumb and thenar muscles. Bilateral affection is rarer [5] than unilateral affection and those without thumb hypoplasia is extremely rare.

Diagnosis of absent FPL is made when a patient presents with inability to actively flex the Interphalangeal joint of the thumb with absent flexor crease, less prominent or absent dorsal wrinkles. There could be hypoplasia of thenar muscles which is not present in our case [4].

Most cases reported in the literature are in Children under 15years [3, 4, 5, 6], while few reports are in adults [7, 8]. Plain radiographs, ultrasound scan, computerized Tomography (CT) Scan, Magnetic Resonance Imaging (MRI) scan of the hand could help to confirm and document. The diagnosis of absence (agenesis), hypoplasia or atrophy of the thenar muscles and tendons may be demonstrated on imaging [3, 4, 7].

Treatment of choice for absent FPL tendon, where and when necessary is surgical either as a one- staged or two staged reconstruction using the Flexor Digitorum Superficialis (FDS) tendon of the ring finger followed by rehabilitation [1, 5, 7].

In our case the patient, though young, has adapted and showed no functional limitation and the mother/parent did not desire surgical intervention at this time [3].

Conclusion

Bilateral congenital absence of FPL without thumb hypoplasia is a rare musculoskeletal anomaly. Most cases in the literature are in paediatrics age group with few reported cases in adults. Treatment is by tendon reconstruction where and when indicated followed by rigorous rehabilitation program.

Acknowledgement

I acknowledge the assistance of Dr Adetokunbo, Consultant Radiologist, State Hospital, Abeokuta, Ogun State, Nigeria for the ultrasound scan images.

Funding: None

Conflict of Interest: No

References

1. Yavari M, Farzam R, Riyahi A. Tendon Transfer in Congenital Deficiency of Flexor Pollicis Longus World J Plast Surg,2017;6(1):123-124.
2. Samon J, Wynkoop A, Bowman S, Varjash M. Isolated Flexor Pollicis Longus Hypoplasia with absence of the InterPhalangeal Crease: A Case Report and Review of the Literature The Internet Journal of Hand Surgery, 2016, 7(1).
3. Demirsaren ME, Afandiyer K, Durgun M, Kilicarshan K, Yorubalut M. Congenital Absence of Flexor Pollicis Longus Tendon without Associated anomalies of Thumb Hypoplasia: A Case Report and Review of the Literature. Hand,2007;2:184-187.
4. Chandhary V, Sehgal H, Bano S, Pamar PR, Kumar S. Bilateral Congenital absence of Flexor Pollicis Longus with thumb hypoplasia and thenar atrophy. Indian Journal Radiology Imaging,2014;24:268-70.
5. Thomas C, Mathiranam T. Coup absence of FPL without hypoplasia of the thenar Musdon. Journal of Hand Surgery (British and European),1993;24B:3:385-386.
6. Dalitan IM, Satria O, Purwantono K. Bilateral Isolated absence of FPL tendon: report on a rare case management. Journal of Orthopa of Indonesia JOT I, 2019, 2(3):J.
7. Kumar R, Singh NK, Kumar S. Congenital bilateral absence of Flexor Pollicis Longus Tendon without associated anomalies of thumb hypoplasia: A Case Report. India Journal Case Reports,2020;6(5):244-246.
8. Suresh SS, Abraham R, Kumar SS. Absence Flexor Pollicis Longus: Case Report with Review of Literature. Hand,2009;4(1):74-77.