



A study on the different types of surgical interventions for Bennett fracture's treatment

Zeshan Ali Khan¹, Sajid Javed², Rana Dawood Ahmad Khan³, Khawar Shahzad⁴

¹ Assistant Prof. Orthopaedic Department DHQ Teaching Hospital Faisalabad, Pakistan

² Senior Resident Orthopaedic Department DHQ Teaching Hospital Faisalabad, Pakistan

³ Associate Prof. Head of Orthopaedic Department DHQ Teaching Hospital Faisalabad, Pakistan

⁴ Senior Registrar Orthopaedic Department DHQ Teaching Hospital Faisalabad, Pakistan

Abstract

Objective: The objective of this study was to investigate the method for treatment of BF (Bennett fractures).

Methodology: We included 60 patients with BF (Bennett's Fracture). Mean age of subjects was 33 years. We treated all the patients surgically with ORIF (Open Reduction and Internal Fixation); 20 cases with K wires, 9 patients with the use of mini T plate of titanium, and 31 patients with the use of osteosynthetic screws.

Result: There was healing and full functional recovery of Bennett fractures between 4 to 8 weeks. We found no evidences of surgical complications, instable movement of trapeziometacarpal joint and degenerative alterations after surgical intervention. Removal of the K wires from 20 patients was carried out between 5 to 7 weeks, whereas there was no removal of other osteosynthetic materials.

Conclusion: Findings of this study confirmed that there is no ideal method for treatment of all the patients having Bennett fractures. However, according to the Bennett fractures, it is much vital to select the osteosynthetic material. It is important to provide the surgical treatment in early possible time even if the dislocation of the fracture is 1mm.

Keywords: K-Wires, osteosynthesis, bennett fractures, complication, instable, intervention

Introduction

Among the fractures of thumbs are intra-articular fractures involving CMC (Carpometacarpal) joint of thumb [1]. Bennett for the very first time described this fracture in year 1882 [2]. Continuous research after that was unable to find a standard procedure for the treatment of all the patients [3]. There are reciprocal interlocking saddles in the thumb's Carpometacarpal joint that allow extension and flexion as well as adduction and abduction [4]. Cooney characterized the articular surface as the universal joint with its axial and longitudinal rotation restricted by its ligaments, tendon extrinsic muscle and capsule [5]. Bennett fractures with other fractures at metacarpal's base, is the outcome of and force axially directed on metacarpal of thumb whereas it is flexed partially [6]. There is dominancy of the male patients in this injury with a female to male ratio as 1:10. Gedda stated that about 50% of Bennett fractures normally occurred in the patients with less than 30 years of age [7].

History in the treatment of this complication showed complete disagreement. Originally, treatment of Bennett fractures was purely conservatively, even Bennett also showed his dissatisfaction with the outcome of his 1st case [8]. Miles and his colleague Struthers, in 1904, treated Bennett fractures by thumb splinting in abduction and manipulation for 2 weeks. But, when there was no achievement of reduction, encouragement of active movement was carried out. There was ultimate good prognosis in the not treated patients, though treated patients obtained good function [9]. Gedda confirmed it in year 1954 and similar was

done by Charnley in year of 1957. Robinson was not satisfied with the mentioned treatment because he observed the recurrence of displacement. He introduced his method that consisted immobilization with plaster of Paris in combination with the skin traction on thumb got by adhesive straps engaged to buckles which were incorporated into the splint of plaster. There were unsatisfactory outcomes of the conservative treatment of Bennett fractures as found by many professionals as Gedda, Iselin, Blanquernon and Benoist, Griffiths and Charnley [10]. In 1908, there was start of surgical treatment of Bennett fractures when Lambotte performed the 1st internal fixation and open reduction of fragments with help of fine nail, it was stated in 1913. Johnson adopted the method of combining the manipulative reduction with skeletal fixing in year of 1944. Wagner in 1951 used similar technique with passing a wire. Ellis was the only person who gave exposure to the trapeziometacarpal joint and then inserted 2 pins in it [11]. Gedda and Moberg stated a volar method to fracture, in which they fixed the fracture with the use of 1 or more wires giving passage through small fragment to the large bone's part. Division of the base of metacarpal into 3 zones was provided by Buechler (Figure-1). Zone-2 was the largest zone. Fractures of this zone develop the post-traumatic alterations. Fracture of Zone-1 and Zone-3 are on the corners of 1st metacarpal base. There are infrequent complications in these zones as compared to Zone-2 [4]. Recently, treatment of Bennett fractures is being carried out conservatively only when there is no displacement of

fragments. There is always indication of surgical intervention because of the displacement of joint because of its biomechanics.

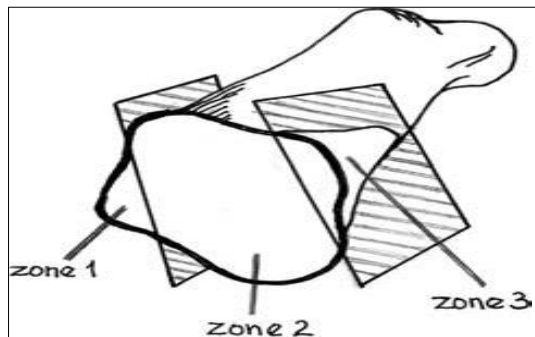


Fig 1

Methodology

There were 60 patients with Bennett fractures (two-part fracture, Figure-2), who got fracture in period of last 5 years from 2014 to 2019. All these patients underwent surgical intervention with osteosynthesis. The mean age of patients was 33 years with a median age of 28 years. Mean age of 33 males was 30 years with median age of 28 years and mean age of 17 female patients was 42 years with median age of 37 years. Female to male ratio in this research study was 1:4.6. We collected the data as age, gender, fracture type, osteosynthesis type utilized and total duration after fracture until the surgery of the patient. We measured the range of thumb's motion before and after the surgery. We recorded two measurements, RA (Radial Abduction) and Opposition. Normal function's Radial Abduction is from 0° to 80°. Opposition is the motion of the thumb to maximal Radial Abduction position to the top of the 5th metacarpal bone towards palmar side.

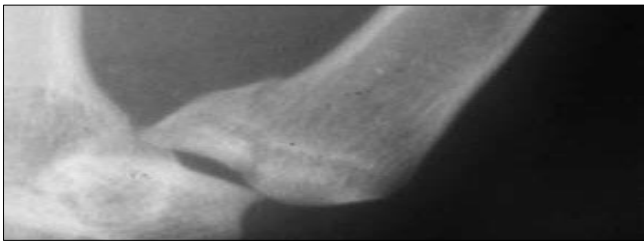

Fig 2

We measured the Radial Abduction as 30.0° in 6 patients, 35.0° in only 2 patients, 40.0° in 15 patients, 45.0° in 20 patients and 50.0° in 7 patients before surgery. 1cm measurement of Opposition was present in 17 patients, 2cm in 30 patients and 3cm in 3 patients before surgery. Most of the Bennett fractures were the outcome of fall. 34 patients fell, 5 fell from motor bike, and 5 from bicycle, 4 from horse, 12 from some height. 7 patients fell from standing level, 20 got injury with hits, 15 got injury in fist fighting and 18 from road traffic accidents. All the patients of this research work underwent radiology diagnostic before surgery. We considered computed tomography when needed. Impacted articular surface may be a possible reason of insufficient reduction. We utilized computerized tomography for 31 out of total 60 patients. All the patients underwent surgery under intravenous anesthesia. The selection of the osteosynthetic device was depending upon the fracture type (Fig-1). Incision of our

operation was 2 to 3 cm long (Fig-3).

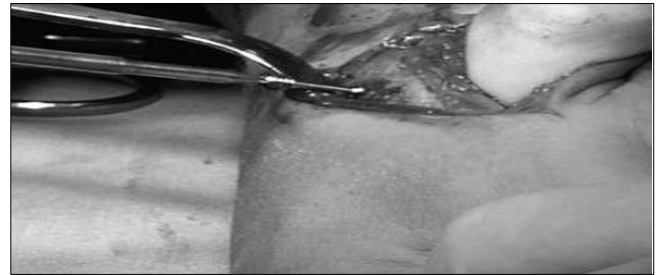

Fig 3

When bone is very small, K-wire (with fragment consideration) is utilized (Figure-4). We utilized 1.50 mm mini Herbert screws made up of titanium (Fig-5) and standard 2-4 mm titanium Herbert screws (Fig-6), 3.20 mm titanium Twin Fix screws (Fig-7). We applied them on guide wires and mini 1.30 mm thick T plates of titanium with six holes, embedded with 2.30 mm titanium cortical screws (Fig-8). We treated 20 patients with use of K wires, 9 patients with mini T plate, and 31 patients with screws (15 patients with the use of Herbert screws, 6 patients with use of AO screws and 10 patients with use of Twin Fix screws).

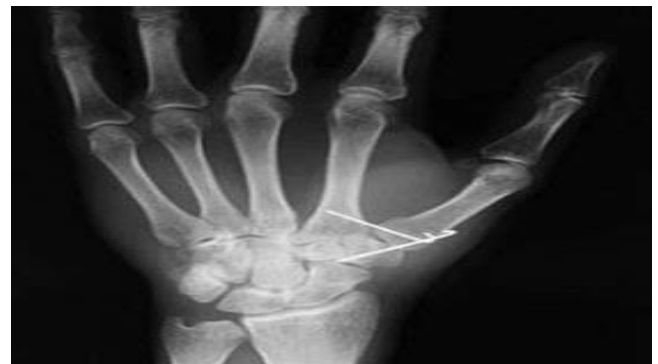

Fig 4

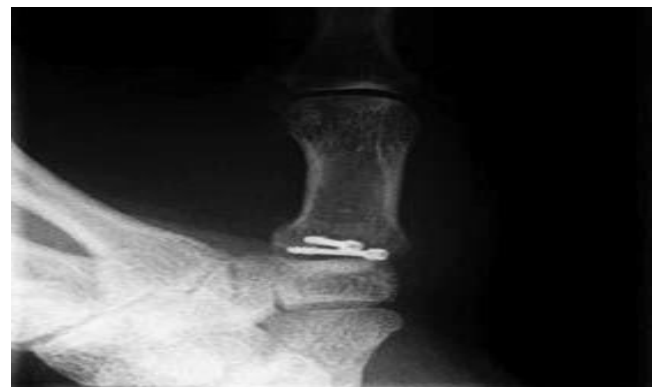

Fig 5

We made the X-ray control immediately after surgery, after one week and after one month. Titanium was the main element used for the formation of all used material as screws and mini T plates, so their removal was not much important. Patients were present without any immobilization who got treatment with screws or plates. There was beginning of rehabilitation in these patients two

days after the surgical intervention. We removed the K-wires 5 to 7 weeks after the surgery. After the removal of the splint, these patients also started rehabilitation. All the patients achieved follow up for the period of six months even though they attained the complete function.

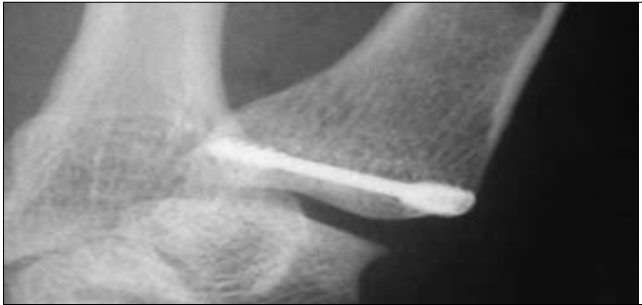

Fig 6

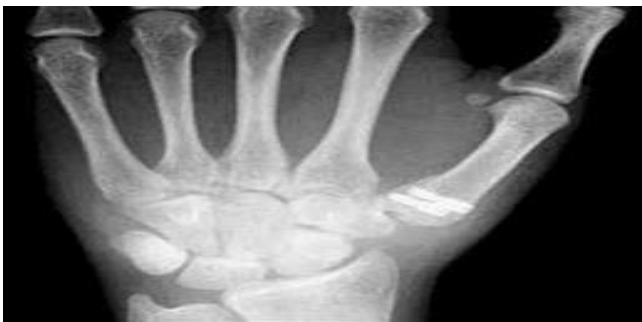

Fig 7

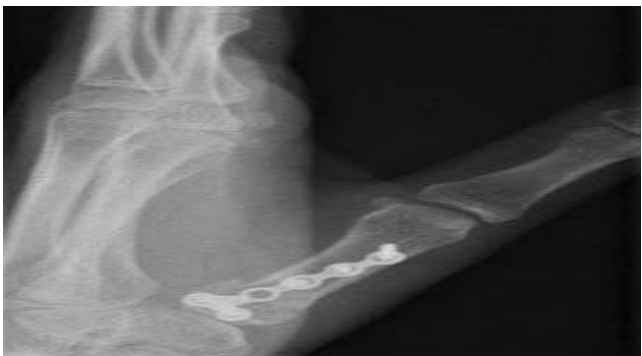

Fig 8

Results

All our patients who underwent surgery, were diagnosed with Bennett fractures (1st metacarpal base fracture). Healing duration was 4 to 7 weeks. We can see the healing of fracture on the x-rays taken as elaborated in the post-surgical treatment. We selected different methods of osteosynthesis according to the type of Bennett fractures. Positive outcomes in all the patients are the sign that osteosynthetic material's type was not deciding feature in healing. There was complete function recovery (Radial Abduction and Opposition) from 4 to 8 weeks. Within a period of four weeks, twenty one out of 60 patients obtained complete recovery of function. Within 5 weeks, 28 out of 60 patients got recovery, in 4 weeks 11 patients recovered, in 5 weeks 4 patients recovered and in 6 weeks 16 patients recovered. There was

exception of only one elder patient who fell down and he underwent surgery on same day with use of K wires. There was presence of degenerative alterations to first Carpometacarpal joint in that patients before injury, with restricted thumb function and hence that patient did not recover the complete function.

This elder patient was unable to get better than Radial Abduction 65° and Opposition 0.50 cm which were measured after 12 weeks of surgery. None of the other patient exhibit degenerative alterations after surgical intervention. There was complain of pain from 10 patients which persisted to 3 months after surgical intervention. The pain remained the part of motion which met satisfaction after 6 weeks of surgery. There were no other serious complications as bone infection or nerve damage. There was no indication of reoperation in our patients. Removal of the K-wires was carried out in 20 patients with local anesthesia for short term after 5 to 7 weeks, whereas all other osteosynthetic material of titanium in 40 was not removed as AO screws, screws, mini T plates, Herbert screws and Twin-Fix screws. No patient appeared with any evidence which showed the extraction of that material.

Discussion

There is very rare prevalence of the intra articular fractures of the base of thumb metacarpal. These fractures are 1.40% of all the fractures of hand, although some researchers placed this prevalence as very low as 0.64% [12]. Decrease in these fractures is important for power grip as well as normal function of hand. Pellegrini and Burton gave the recommendation of percutaneous fixation of pin and closed reduction if there was displacement of the fracture was less than 3 mm or if there was displacement of 3 or more diameter. Gedda stated the association of arthritis radiographically proved and persistent fracture displacement [3,4]. We utilized this technique with help of K-wires; but found them percutaneous (Figure-4). There were many reasons behind not preferring the percutaneous pinning. Brazier compared the direct osteosynthesis and closed pinning for treatment of Bennett fractures and discovered that post-surgical function was much better after direct osteosynthesis than the closed pinning [12].

In some other kinds of the upper extremity surgery where there was a fragment of small bone like with the capitellum humeri fracture, we experienced the utilization of various kinds of screws for the osteosynthesis as we showed here with Bennett fractures. Soyer suggested that there should be one mm or less reduction to decrease the danger of radiographic arthritis. Very first recommendation of a reduction with lower than one mm fracture displacement may be obtained in the patients of Bennett fractures, was made in the year of 1993. In a current research, Carlsen and Moran stated that there is need of the use of open surgery for patients of Bennett fractures with irreducible reduction of one mm or more than this [13]. We used the screws in our treatment if we found the involvement of Zone-2. Utilization of K wires was carried out for fractures present in Zone-1 or Zone-3. It is to be noticed that diameter of the screw thread should be 30.0% or more less of width of fracture's cortical surface to reduce the further damage to the fragment [14]. We performed the osteosynthesis with a 1.30 mm thick mini T plate having six holes (Figure-8) when there was fracture in large fragments. There was not any report about the instability of the trapeziometacarpal joint after surgery. We also checked the instability of this joint according to the suggestion of Nagaoka.

Conclusion

Findings of this research study confirmed that there is no ideal method for all the patients having Bennett fractures. However, it is much vital to select the osteosynthetic material for the treatment of Bennett fractures according to its type. This is the early possible treatment through surgery even if the dislocation of the fracture is one mm.

References

1. Pollen A. J Bone Joint Surg Br, 1968, 50:91.
2. Salgeback S, Eiken O, Carstam N, Ohlsson Nm, Scand J Plast Reconstr Surg, 1971, 5:142.
3. Spangberg O, Thoren L. J Bone Joint Surg Br, 1963, 45:732.
4. Thoren L. Acta Chir Scand, 1956, 110:485.
5. Haines Rw, J Anat, 1944, 78:44.
6. Napier J. J Anat, 1955, 89:362.
7. Pellegrini Vd Jr, Hand Clin, 1988, 4:87.
8. Pieron Ap, Acta Orthop Scand, Suppl, 1973, 148:1.
9. Cooney W, Chao E. J Bone Joint Surg Am, 1977, 59:27.
10. Cooney W, Lucca M, Chao E, Linscheid Rl. J Bone Joint Surg Am, 1981; 63:1371.
11. Griffiths J. J Bone Joint Surg Br, 1964; 46:712.
12. Gedda Ko, Moberg E, Acta Orthop Scand, 1953, 22:249.
13. Jupiter J, Ring Dc. Ao Manual of Fracture Management Hand and Wrist (Stuttgart and Thieme, New York), 2005.
14. Brüske J, Bednarski M, Niedzwiedz Z, Zyluk A, Grzeszewski S. Acta Orthop Belg, 2001, 67:368.