



---

## **Lipoma Arborescens-a rare cause of monoarticular knee joint swelling in adolescents-case report**

**Vibhav Gandhi<sup>1</sup>, Shagun Shory<sup>2</sup>, Avinash Kumar<sup>3</sup>, Mohit Jindal<sup>4</sup>, Mohit Goyal<sup>5</sup>, Nipun Aggarwal<sup>6</sup>, Vipul Shory<sup>7</sup>, Ayushi Bansal<sup>8</sup>**

<sup>1</sup> Department of Orthopaedics, Punjab Institute of Medical Sciences, Jalandhar, Punjab, India

<sup>4,5</sup> Department of Orthopaedics, Kalpana Chawla Government Medical College, Karnal, Haryana, India

<sup>2</sup> Department of Anaesthesiology, S.B.K.S. Medical Institute and Research Centre, Vadodara, Gujarat, India

<sup>3</sup> Department of Orthopaedics, Mata Gujri Memorial College, Kishanganj, Bihar, India

<sup>5</sup> Department of General Surgery, S.B.K.S. Medical Institute and Research Centre, Vadodara, Gujarat, India

<sup>6</sup> Department of Pathology, Kalpana Chawla Government Medical College, Karnal, Haryana, India

---

### **Abstract**

Lipoma Arborescens is a slowly progressive intraarticular lesion of knee characterised by substitution of sub synovial tissue with fat cells and villous transformation of synovium. It is a rare entity with limited literature. We present a case of lipoma arborescens in 17 year old boy who presented with complaints of mono-articular swelling of left knee for 2 years with history of antecedent trauma. MRI showed frond like masses present in supra and infrapatellar region with high signal intensity on T1W and Intermediate signal intensity on T2W, consistent with fat. He was managed with open synovectomy which showed yellowish white polypoidal and villous masses of adipose tissue. Masses were sent for histopathology which showed hypertrophic villous projections of fat lined by synovial cells. Patient became asymptomatic postoperatively and improved functionally.

**Keywords:** Lipoma Arborescens, open Synovectomy, mono-articular knee swelling

---

### **Introduction**

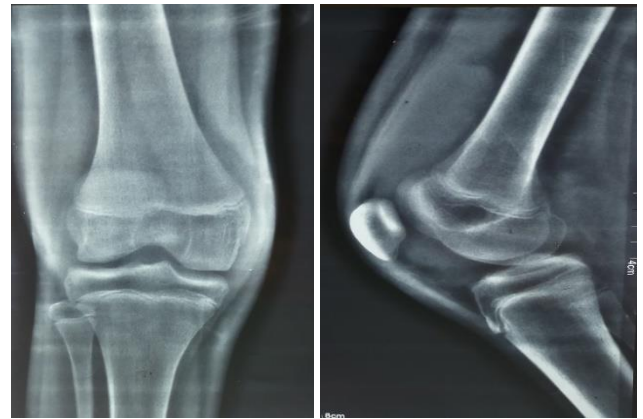Lipoma Arborescens is a rare articular lesion consisting of subsynovial villous proliferation of mature fat cells <sup>[1]</sup>. The knee joint is the most commonly involved joint <sup>[2]</sup>. The term arborescens in Latin means “tree like” which describes the characteristic villous and frond like morphology of this condition <sup>[3]</sup>. The term lipoma is misleading as it does not show any features of a neoplasm the condition is rare with unclear aetiology. It is usually found in 9-68 years of age. It is extremely rare in children. It is most commonly mono-articular but can present as poly-articular or bilateral involvement <sup>[3]</sup>. Although suprapatellar pouch of knee joint is commonly involved, it has been reported in shoulder, hip, elbow and wrist. There have been reports of involvement of subdeltoid and bicipital bursa and the synovial sheath of peroneal tendons. <sup>[4-6]</sup> MRI is the imaging modality of choice <sup>[3]</sup>. Characteristic MRI feature of lipoma arborescence is high signal intensity villous mass on T1 and T2 weighted sequence with signal intensity similar to fat. The recommended treatment is open or arthroscopic synovectomy. The recurrences are uncommon.

### **Case report**

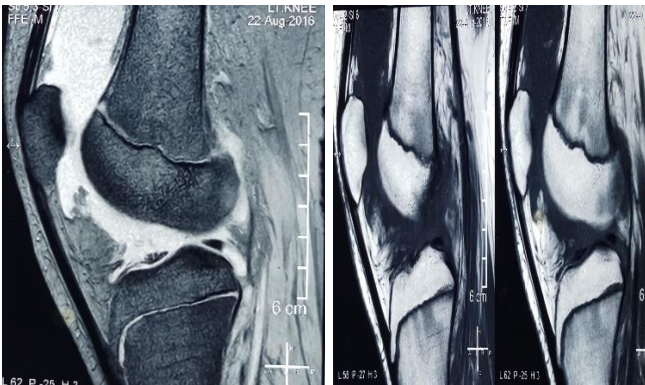
17 year old boy presented with history of swelling in the left

knee for 2 years which was initially painless now painful. Patient had history of trauma 2 years back following which he was investigated in tertiary care institute and found to have no bony injury. He was managed with a cylindrical slab for 2 months. Following the removal of slab patient remained asymptomatic for 1 month then developed swelling of the knee. Patient was evaluated for causes of mono-articular knee swelling, RA factor was negative, Uric acid was within normal limits, ESR was 54. Synovial fluid analysis was done which showed no crystals and pus cells. Patient was managed conservatively for few months on anti-inflammatory drugs and rest. Knee swelling did not resolve and patient was subjected to MRI of knee which showed frond like mass present in supra and infrapatellar region which had high signal intensity on T1 weighted images and intermediate signal intensity on T2 weighted images which was consistent with adipose tissue. Moderate joint effusion was observed and no ligamentous injury was seen. Patient was advised surgery but failed to follow up. Now he presented to us with mono-articular knee swelling. On examination moderate effusion of knee joint was present

with doughy feeling in supra patellar pouch. Knee was grossly tender. Range of movements of left knee was restricted with 0-110 degree flexion. Lymphadenopathy was absent. Opposite knee and other joints were normal. Repeat ESR was 40. Xrays showed no gross abnormality. He was taken up for arthroscopy of left knee with synovectomy and excision of mass. Intraoperatively it was observed that there was synovial hypertrophy with yellowish white masses in supra and infrapatellar region. Masses were excised and sent for biopsy. On histopathology hypertrophic villous projections were seen which were lined by synovial cells with variably scattered inflammatory cells, predominantly lymphocytes and plasma cells. Patient was followed regularly in post-operative period at 1 week, 2 weeks, 4 weeks and 12 weeks post- surgery. Patient returned to his routine activities and had good functional outcome.



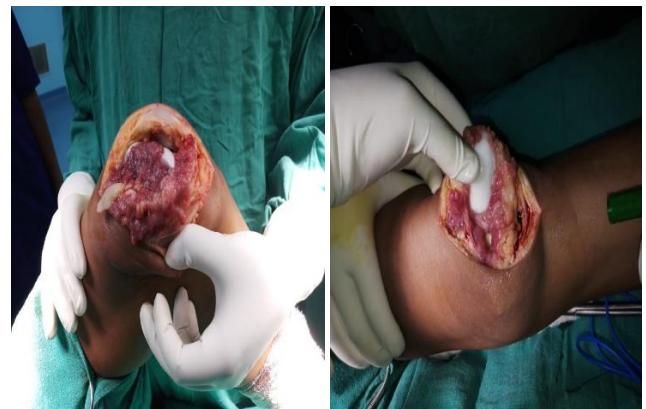
**Fig 3:** Plain radiographic images of left knee joint, antero-posterior and lateral views.



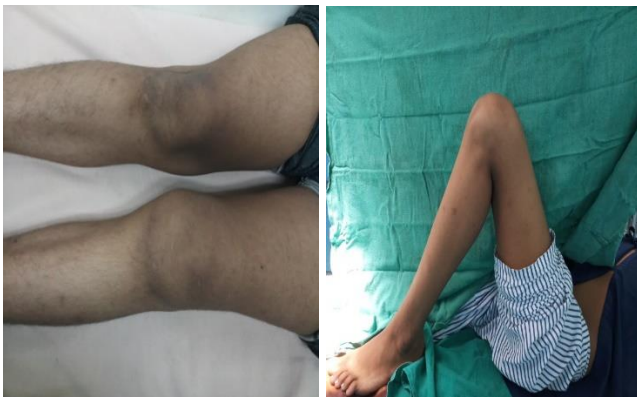**Fig 1a:**

**Fig 1b**

Figure 1a & 1b: T2 and T1 weighted MRI images of the knee joint of patient depicting villous fatty tissue growth in infrapatellar region.



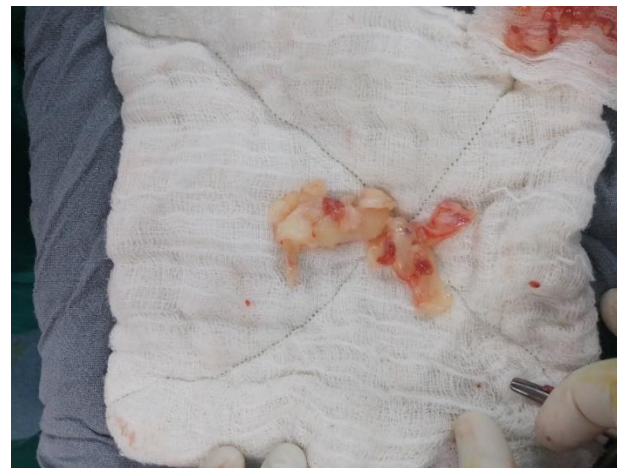**Fig 4:** Intraoperative pictures showing synovial hypertrophy and yellowish white mass in the suprapatellar region of left knee joint.



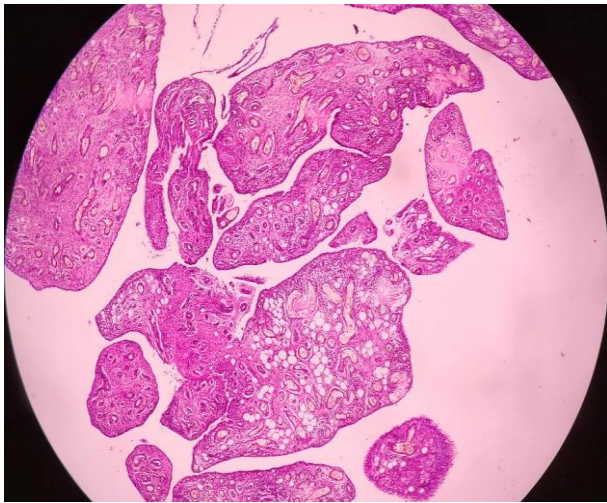
**Fig 2a**

**Fig 2b**

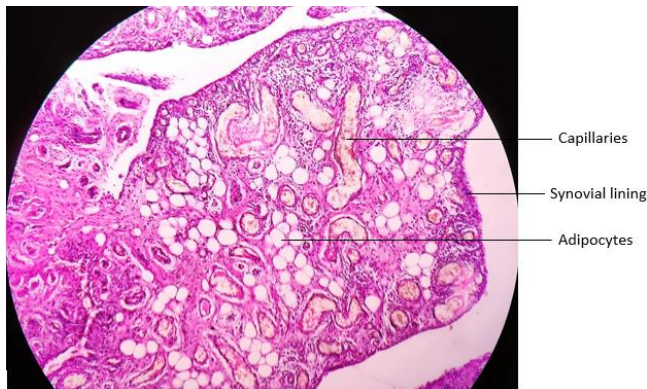
**Fig 2a & b:** Clinical pictures of left knee of the patient demonstrating swelling of left knee and decreased range of motion.



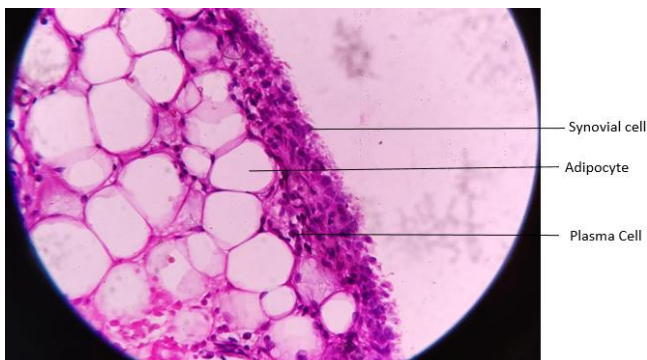
**Fig 5:** Gross appearance of Lipoma Arborescens- appears as yellowish white polypoidal mass.



**Fig 6a:** Scanner view showing Villous like structures lined by synovium



**Fig 6b**



**Fig 6b & c:** 10x and 40x magnification showing –villous structures are lined by synovial cells and contain within them proliferating thin walled capillaries and benign adipocytes along with dense, diffuse plasmacytic infiltrate.

**Discussion**

Lipoma arborescens (LA) is a rare intra-articular lesion characterised by diffuse replacement of subsynovial tissue with mature adipocytes and villous proliferation of overlying synovium. It was first described by German surgeon, Albert Hoffa in 1904 and was later described in detail by Arzimanoglu in 1957 [7, 8]. It most commonly affects knee but lesions in other

articular sites like hip, ankle, wrist, elbow and shoulder; as well as extra articular sites like synovial sheath and bursae. Peak incidence is between 30-50 years but it has been observed between 9 to 68 years of age. No sex preponderance has been observed [3]. Its aetiology is unknown but it has been associated with trauma, degenerative conditions or inflammatory joint diseases. There are two aetiological types of lipoma arborescens, primary and secondary, depending on age of presentation and underlying condition [9, 10].

Primary LA is idiopathic and occurs in younger population between ages 20 to 30 years. Secondary LA is more common and defined as synovial lipomatosis associated with chronic synovial irritation due to degenerative disease, trauma, meniscal injury and infection [3]. It is generally seen in older population. Patients with lipoma arborescens can present with slow progressive swelling, intermittent episodes of joint effusion, restriction of range of motion, locking and pain. On examination the joint can appear effused with a palpable mass in the supra patellar pouch. MRI is the imaging modality of choice for diagnosis of lipoma arborescens. Laboratory findings are nonspecific. Plain radiograph can show soft tissue periarticular soft tissue opacity, osteoarthritic features or non-specific erosion. On ultrasonography a frond like hyperechoic mass is seen that waves during manipulation of joint. CT scan although done rarely may demonstrate villous synovial mass with soft tissue density similar to fat with no enhancement on contrast.<sup>11</sup> Lipoma Arborescens can be distinguished from other intra-articular masses with its pathognomic appearance on MRI. It appears as frond like mass with signal intensity similar to subcutaneous fat on all pulse sequences. It shows high signal intensity on T1 and T2 weighted images which get suppressed on short tau inversion recovery or fat suppression sequences. With contrast the mass does not enhance however synovial layer and joint fluid show enhancement. MRI may also demonstrate joint effusion and degenerative changes like chondropathy and osteophytes [11].

Grossly it appears as yellowish white mass with frond like pattern. On histopathology there is papillary proliferation of synovial villi with substitution of subsynovial tissue by mature adipocytes. Overlying synovium contains mononuclear infiltrates and the synovial cells are enlarged with eosinophilic cytoplasm [12]. Treatment of lipoma arborescens is surgical excision either open or arthroscopic. Other treatment modalities like yttrium 90 radio synovectomy and chemical synovectomy with osmic acid has also been described [13]. Recurrence after excision is uncommon [14].

**Conclusion**

Lipoma arborescens is a rare cause of intra articular mass but its possibility needs to be kept in differential diagnosis. Its characteristic appearance on MRI is pathognomic and helps in differentiating from other pathologies. Open or arthroscopic synovectomy gives satisfactory results with low incidence of recurrence.

**Corresponding Author:** Dr. Vibhav Gandhi, Senior Resident, Department of Orthopaedics, Kalpana Chawla Government Medical College, Karnal, Haryana.

## References

1. Hallel T, Lew S, Bansal M. Villous lipomatous proliferation of the synovial membrane (lipoma arborescens). *J Bone Joint Surg Am.* 1988; 70:264-70.
2. Yan CH, Wong JWK, Yip DKH. Bilateral knee lipoma arborescens: a case report. *J Orthop Surg Hong Kong.* 2008; 16:107-10.
3. Sanamandra SK, Ong KO. Lipoma arborescens. *Singapore Med J.* 2014; 55:5-11.
4. Senocak E, Gurel K, Gurel S, Ozturan KE, Cakici H, Yilmaz F, *et al.* Lipoma arborescens of the suprapatellar bursa and extensor digitorum longus tendon sheath: report of 2 cases. *J Ultrasound Med Off J Am Inst Ultrasound Med.* 2007; 26:1427-33.
5. Laorr A, Peterfy CG, Tirman PF, Rabassa AE. Lipoma arborescens of the shoulder: magnetic resonance imaging findings. *Can Assoc Radiol J J Assoc Can Radiol.* 1995; 46:311-3.
6. Dawson JS, Dowling F, Preston BJ, Neumann L. Case report: lipoma arborescens of the sub-deltoid bursa. *Br J Radiol.* 1995; 68:197-9.
7. Hoffa A. The influence of the adipose tissue with regard to the pathology of the knee joint. *JAMA.* 1904; 43:795-6.
8. Arzimanoglu A. Bilateral arborescent lipoma of the knee. *J Bone Joint Surg Am.* 1957; 39:976-9.
9. Vilanova JC, Barceló J, Villalón M, Aldomà J, Delgado E, Zapater I. MR imaging of lipoma arborescens and the associated lesions. *Skeletal Radiol.* 2003; 32:504-9.
10. Patil PB, Kamalapur MG, Joshi SK, Dasar SK, Rao RV. Lipoma Arborescens of Knee Joint: Role of Imaging. *J Radiol Case Rep.* 2011; 5:17-25.
11. De Vleeschhouwer M, Van Den Steen E, Vanderstraeten G, Huyse W, De Neve J, Vanden Bossche L. Lipoma Arborescens: Review of an Uncommon Cause for Swelling of the Knee. *Case Rep Orthop.* 2016; 2016:1-5.
12. Kulkarni HG, Kulkarni GS, Kulkarni PG. Lipoma Arborescens - Eyes See What Mind Knows! *J Orthop Case Rep.* 2017; 7:59-62.
13. Erselcan T, Bulut O, Bulut S, Dogan D, Turgut B, Ozdemir S, *et al.* Lipoma arborescens; successfully treated by yttrium-90 radio synovectomy. *Ann Nucl Med.* 2003; 17:593-6.
14. Erol B, Ozyurek S, Guler F, Kose O. Lipoma arborescens of the knee joint. *BMJ Case Rep [Internet].* 2013 [cited 2013]. Available from: <https://www.ncbi.nlm.nih.gov/pmc/articles/PMC3645131/>, 2018.