



International Journal of Orthopaedics Research

orthopaedicsjournal.in

E-ISSN: 2663-0923, P-ISSN: 2663-0915

Received Date: 01-02-2019 Accepted Date: 01-03-2019; Published: 08-03-2019

Volume 1; Issue 2; 2019; Page No. 01-03

Transverse process fracture of all five lumbar vertebrae: A rare sports injury

Arjun Rawal¹, Ganesh Singh Dharmshaktu^{2*}

¹ Senior Resident, Department of Orthopaedics, Government Medical College, Haldwani, Uttarakhand, India

² Assistant Professor, Department of Orthopaedics, Government Medical College, Haldwani, Uttarakhand, India

Abstract

Transverse process fracture is an uncommon injury in sports and often follows a high energy contact sport injury. Fractures in isolation are not uncommon and mostly are managed conservatively. Many of these injuries require exclusion and management of associated musculoskeletal or solid organ injuries if present. Simultaneous, multiple and displaced transverse process is an uncommon injury. One such case in a 22 year old soccer player with left side concomitant contiguous transverse process fractures of all lumbar vertebrae (L 1 to L 5) is presented here with relevant details.

Keywords: transverse process, spinal fracture, spine trauma, lumbar spine, injury, sports

Introduction

Transverse processes project laterally from junction of lamina and pedicle of vertebrae and serve as attachment site for important musculature. Avulsion injury of transverse process requires forceful muscle contractions and is overall an uncommon event. The isolated transverse process or spinous process fractures are considered stable and may be neglected if are isolated or minimally displaced^[1, 2]. Isolated transverse process fractures are not uncommon injuries as one study of abdominal trauma cases, 7.3% were found to have these injuries in abdominal helical CT (computerized tomograms) scans.^[3] Isolated transverse process fractures are often detected at initial or incidental investigations. Concomitant fracture of unilateral transverse processes of all lumbar vertebrae is an uncommon injury.

Case report

A 22-year-old male soccer player was brought to us post the match with history of fall on the ground during the match while back-flipping and kicking the ball. He landed on the ground with another player tumbling over him. The exact attitude was not exactly recalled by the patient who completed the match before consulting after the match was over. He had severe left side of the back pain along with tenderness over left para-spinal area of lower back. He was given pain medication, rest and advised radiograph of lower back. The radiograph revealed multiple transverse process fracture of lumbar 1 to 5 vertebrae with wide displacement. He was advised taping and fomentation to relieve pain. The acute pain gradually relieved over two weeks but active sports participation was withheld till complete recovery. There was no neurological deficit or other

injuries to warrant advance imaging. Chronic stretching related pain was noted but was bearable in the following weeks and marked improvement was noted after fifteen weeks of follow up. Meanwhile supervised fomentation, taping and physiotherapy was performed. The pain and disability was markedly improved in the follow up of eight weeks and gentle return of function was noted after eight months. There were, however, no immediate or late complications noted.

Discussion

Transverse process has strong muscle attachments and thus is prone to injury following extraordinary forceful contraction avulsing the muscle with or without bony pedestal like in other anatomical areas.^[4] The sports injuries involving transverse process are rare events and reported as anecdotal case reports or small series in the literature^[5, 7]. Large series in recent literature are related to American football and skiing^[5, 7, 8]. Our case also injured during soccer game and the relation of this game to the injury may be based on the recurrent posture changes and sudden violent contractions of lateral spinal musculature. Report of fracture involving all the lumbar vertebrae transverse process is rare and one recent report has been reported in cricket by Bali *et al.*^[9] (Table.1). Some spinal alignment disorders like displacement or listhesis may also be present in some of these injuries^[10, 11]. The table presented by us describes relevant features of these injuries in sports related events. Various reports link them to solid organ injuries and these injuries thus warrant cautious approach to rule out and suspect associated chest or abdominal injuries^[12]. The quest to diagnose and manage associated skeletal injuries is also

warranted as many of these injuries may have important bony injuries requiring stabilization [13]. These injuries thus should undergo detailed clinical assessment and relevant investigations to rule out significant associated injuries. Our case, fortunately had no major abdominal injury except a small free fluid collection that was not associated with immediate and future morbidity. A supervised physical therapy program is critical in

the recovery and success of which determines future return of play decisions. Careful attention and anticipation of these injuries should be kept in mind in sporting events requiring high energy physical movements or injuries. Good quality studies, however, are required to draft their true incidences, optimum treatment recommendations and long term outcomes.

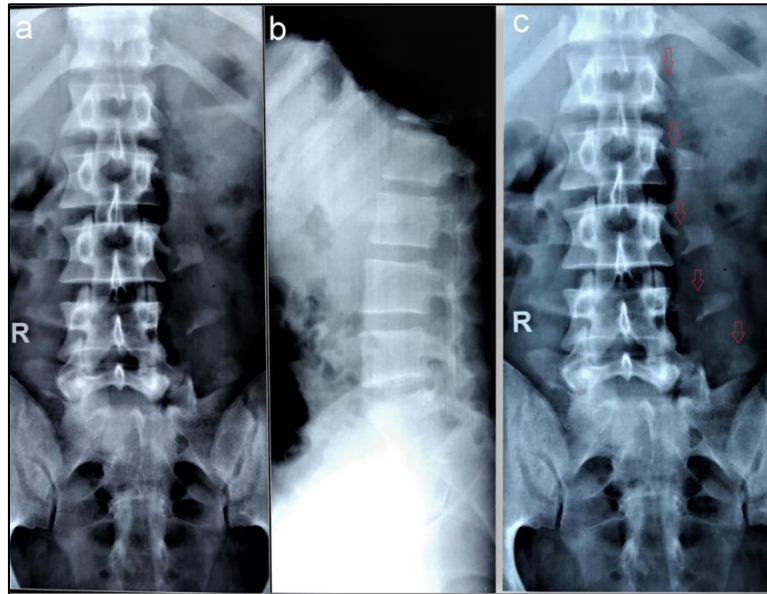


Fig 1: Radiograph of the lumbar spine showing consecutive transverse process fractures in left in anteroposterior view (a) while lateral view showing straightening of spine due to spasm without any vertebrae injury (b). Magnified image showing the displaced fractures (arrow) of transverse process from L1 to L5 on left side (c).

Table 1. Table showing selected reports of transverse process fracture articles following sports related events with relevant details.

Author and year	Transverse process injury	Associated injury	Sports	Mechanism of injury
Tewes et al (1995) ¹	29 cases		American national football league players	Impact and torsion
Brynin et al (2001) ²	L2, L3	-	American football	Speared in the back by another player
Dutson. (2006) ³	L1	Transverse colon rupture	Football	Blunt direct blow from knee of other player
Bali et al. (2011) ⁵	L1,2,3,4,5		Cricket	Repetitive stress
Gertzbein et al. (2012) ⁴	43 fractures	-	Ski, snowboarding	Intense muscle activity avulsions
Gray et al.(2015) ⁶	L2, L3	Mild anterior displacement of L2 injury	Football	Fall from height following overhead kick
Pfister et al. (2016) ⁷	L2,3,4	Old spondylolisthesis	American football	Hit by helmet of opponent following landing after being airborne

Conclusion

A proper anticipation and identification of rare injury pattern like multiple transverse process fractures should be made during contact sports injuries. Exclusion of associated injuries and proper physical therapy consultation is important to optimal recovery.

References

- Bradley LH, Paullus WC, Howe J, Litofsky NS. Isolated transverse process fractures: spine service management not needed. J Trauma. 2008; 65:832-836.
- Homnick A, Lavery R, Nicastro O, Livingstone DH, Hauser CJ. Isolated thoracolumbar transverse process fractures: call physical therapy, not spine. J Trauma. 2007;

63:1292-1295.

3. Patten RM, Gunberg SR, Brandenberger DK. Frequency and importance of transverse process fractures in the lumbar vertebrae at helical abdominal CT in patients with trauma. *Radiology*. 2000; 215:831-834.
4. Dharmshaktu GS, Khan I. Displaced closed avulsion of tibial tuberosity in a parkour enthusiast. *Saudi J Sports Med*. 2017; 17:57-9.
5. Tewes DP, Fischer DA, Quick DC, Zamberletti F, Powell J. Lumbar transverse process fractures in professional football players. *Am J Sports Med*. 1995; 23:507-9.
6. Brynin R, Gardiner L. Missed lumbar transverse process fractures in a high school football player. *J Manipulative Physiol Ther*. 2001; 24:123-6.
7. Dutson SCM. Transverse colon rupture in a young footballer. *Br J Sports Med*. 2006; 40:e6.
8. Gertzbein SD, Khoury D, Bullington A, StJohn TA, Larson AI. Thoracic and lumbar fractures associated with skiing and snowboarding injuries according to the AO Comprehensive classifications. *Am J Sports Med*. 2012; 40:1750-4.
9. Bali K, Kumar V, Krishnan V, Meena D, Rawal S. Multiple lumbar transverse process stress fractures as a cause of chronic low back ache in a young fast bowler- a case report. *SMARTT*. 2011; 3:8.
10. Gray M, Catterson P. Multilevel transverse process fractures in a professional association football player: a case report. *Oxford medical Case Reports*. 2015; 5:288-291.
11. Pfister T, Phillips S, Stratton T. Lumbar transverse process fractures in collegiate male football player. *The Journal of sports Medicine and Allied Health Sciences*. 2016; 2:1.
12. Miller CD, Blyth P, Civil ID. Lumbar transverse process fractures-a sentinel marker of abdominal organ injuries. *Injury*. 2000; 31:773-776.
13. Akinpelu BJ, Zuckerman SL, Gannon SR, Westrick A, Shannon C, Naftel RP. Pediatric isolated thoracic and/or lumbar transverse and spinous process fractures. *J Neurosurg Pediatr*. 2016; 17:639-644.